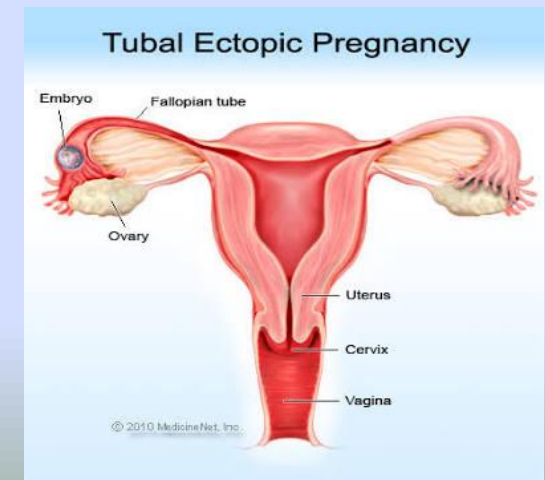
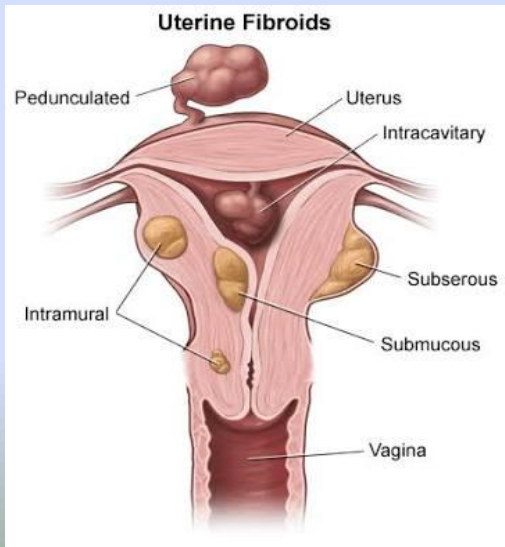


Differential diagnosis of left iliac fossa mass in ladies

Prof Dr/ Alaa El – Suity



**Left iliac fossa mass is divided
into two main categories:**

a) Parietal swellings

b) Intra-abdominal swellings

A) Parietal
swellings:

1-Skin:

- Abscess
- Sebaceous cyst
 - Haematoma
- Haemangioma

- **Subcutaneous tissue:**

- Lipoma
- Neurofibroma
- Neurofibrosarcoma

Muscle layer

- fibrosarcoma

Hernia:

- Incisional
- Paralytic

B) Intra-
abdominal
swelling:

Visceral → in pelvic colon

- Bilharzial mass
- Pelvic carcinoma
 - Diverticulitis
- d. Spastic colon

Tube-ovarian

- Ovarian cyst or tumour
 - Hydrosalpinx
 - Pyosalpinx
- Tubal pregnancy
 - fibroid

- **Renal**

- Ptosed kidney b. ectopic kidney

- **Vascular**

- Left iliac artery aneurysm
Left iliac lymphadenopathy
- Lymphadenitis or Lymphoma

- **Muscular**

- Ilio-psoas abscess

- **Retroperitoneal sarcoma**

Causes of left iliac fossa mass that are exclusively in females
are:

Tubo-ovarian causes:

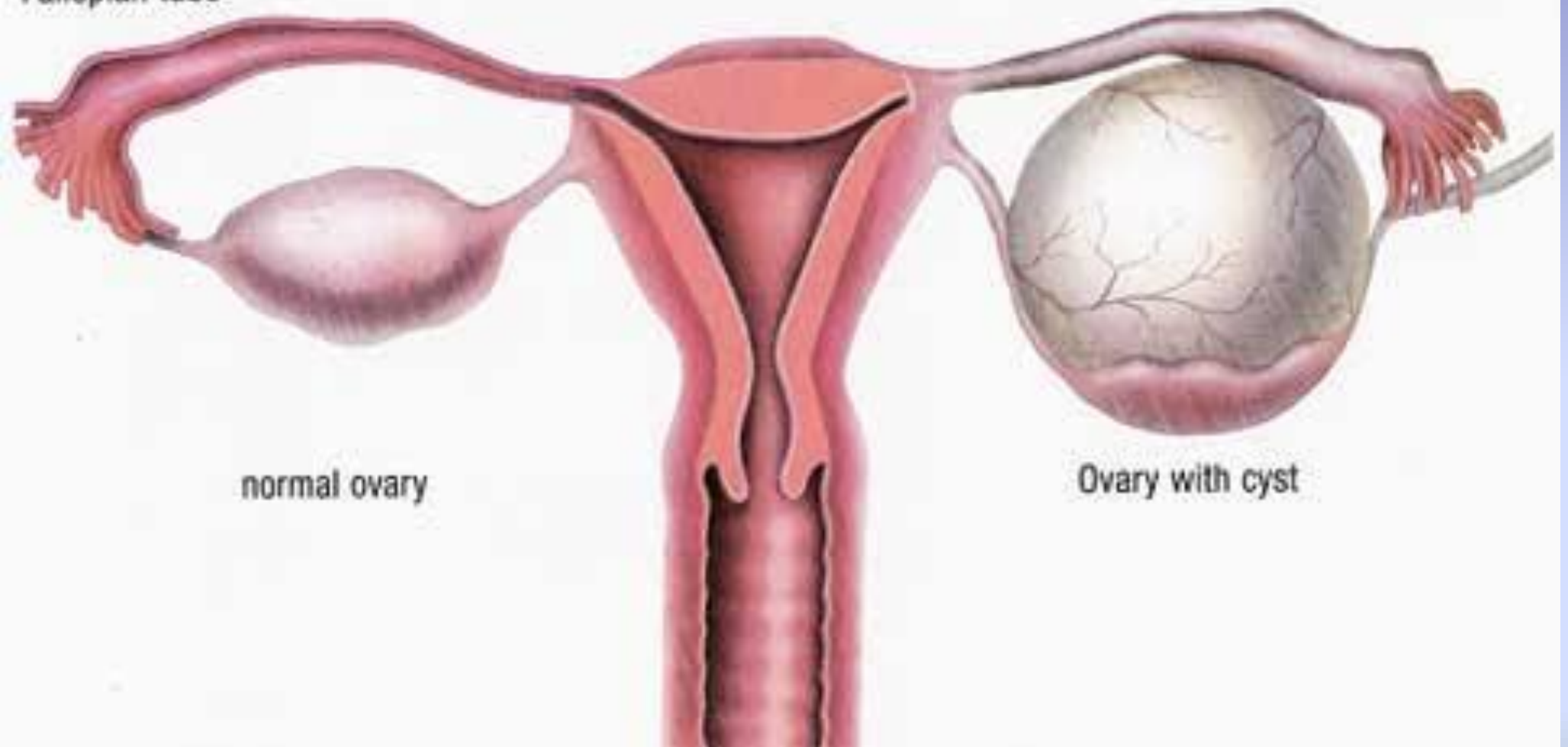
- Ovarian cyst or tumour
 - Hydrosalpinx
 - Pyosalpinx
- Tubal pregnancy
 - Fibroid

• Ovarian Cyst:

Symptoms:

- Nausea
- Vomiting
- Bloating
- Painful bowel movements
 - Pain during sex
- Pelvic pain before or during the menstrual cycle
 - Breast tenderness

Fallopian tube



normal ovary

Ovary with cyst

Diagnosis:

- Ultrasonography
 - CT scan
 - MRI

C37-4.2

20Hz

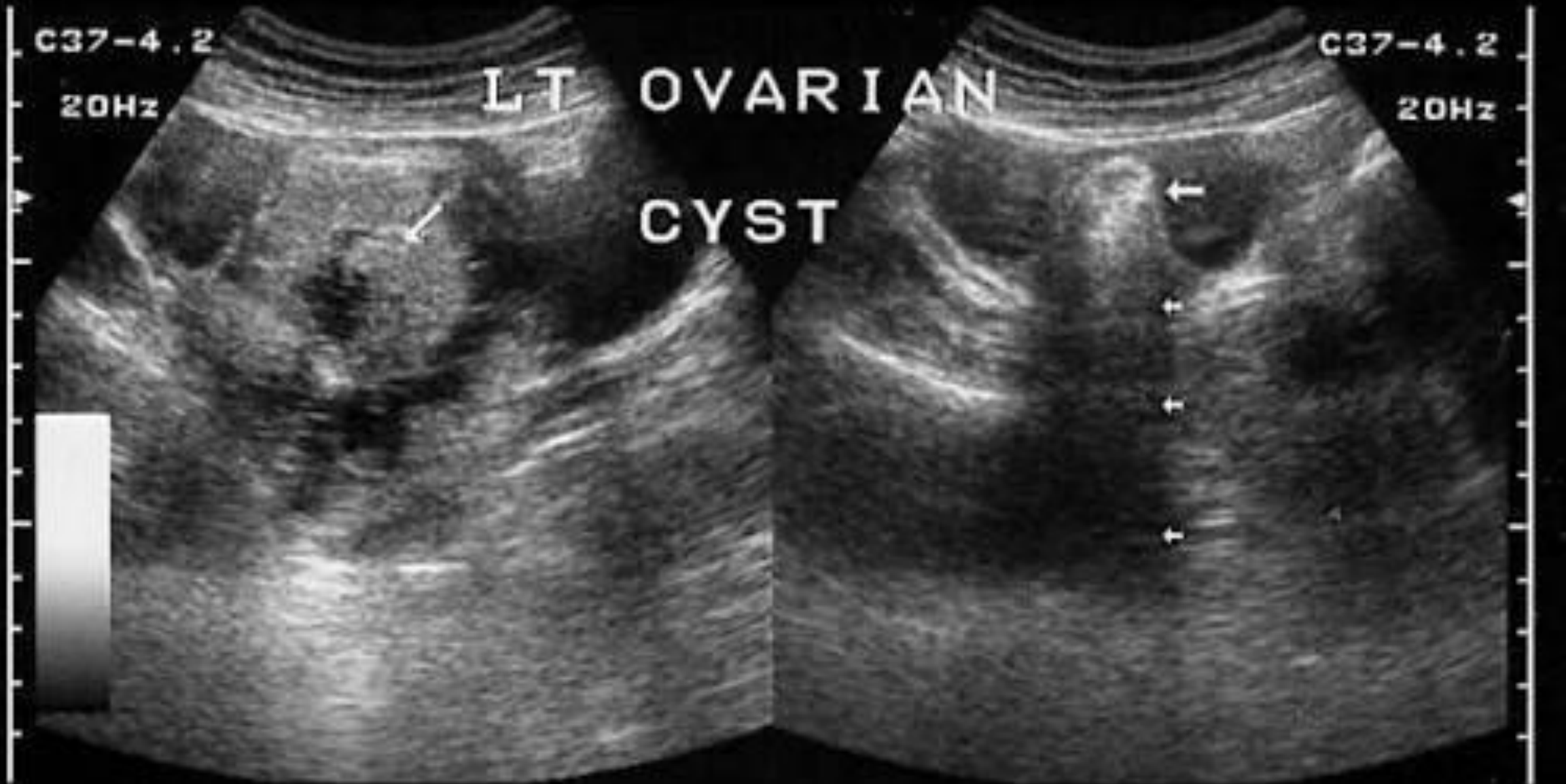
LT OVARIAN

CYST



C37-4.2

20Hz



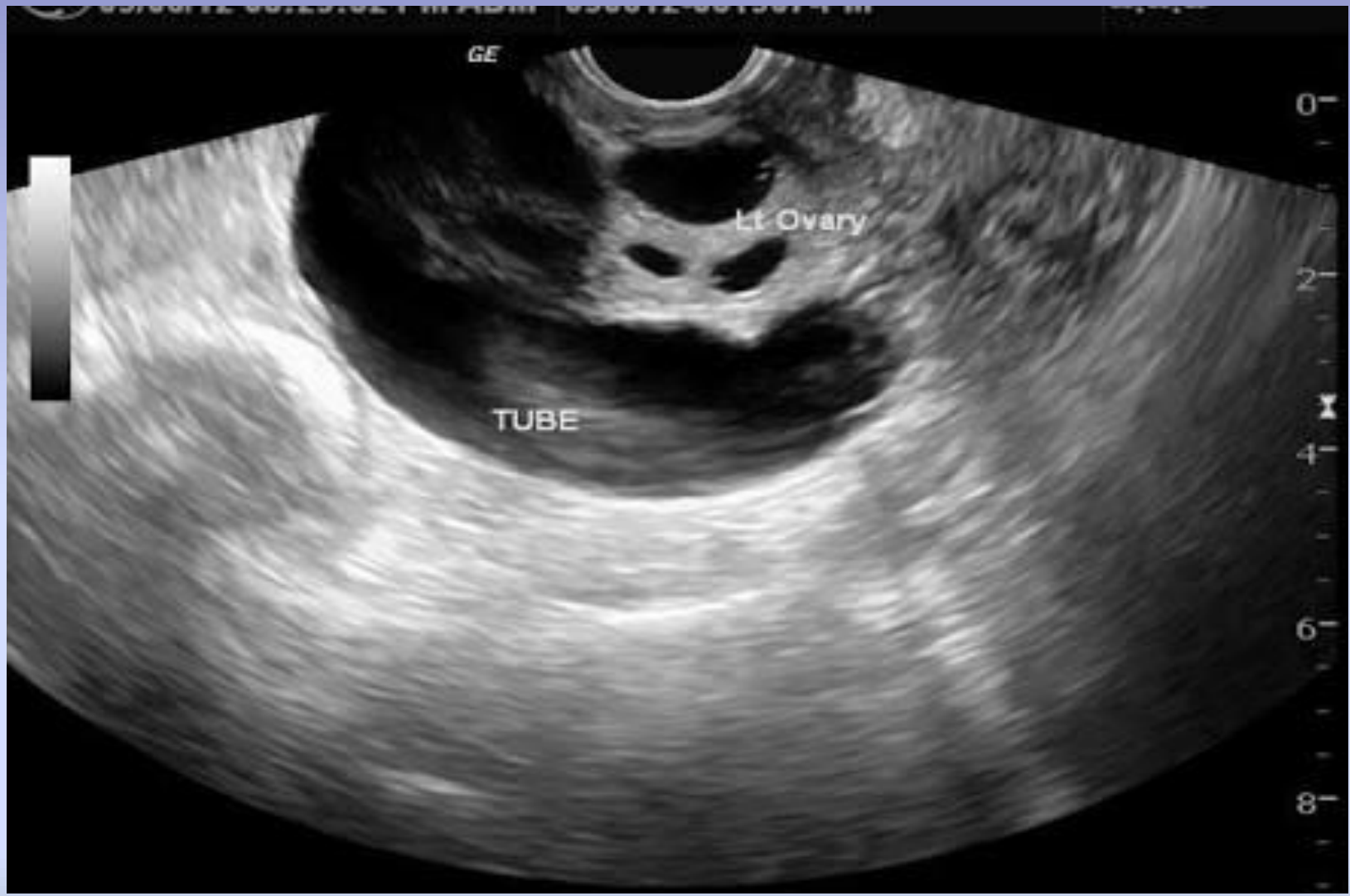Hydrosalpnix and Pyosalpnix:

Symptoms:

- Constant or frequent pain in lower abdomen
 - Vaginal discharge
 - Infertility
 - Fever in pyosalpnix

Diagnosis:

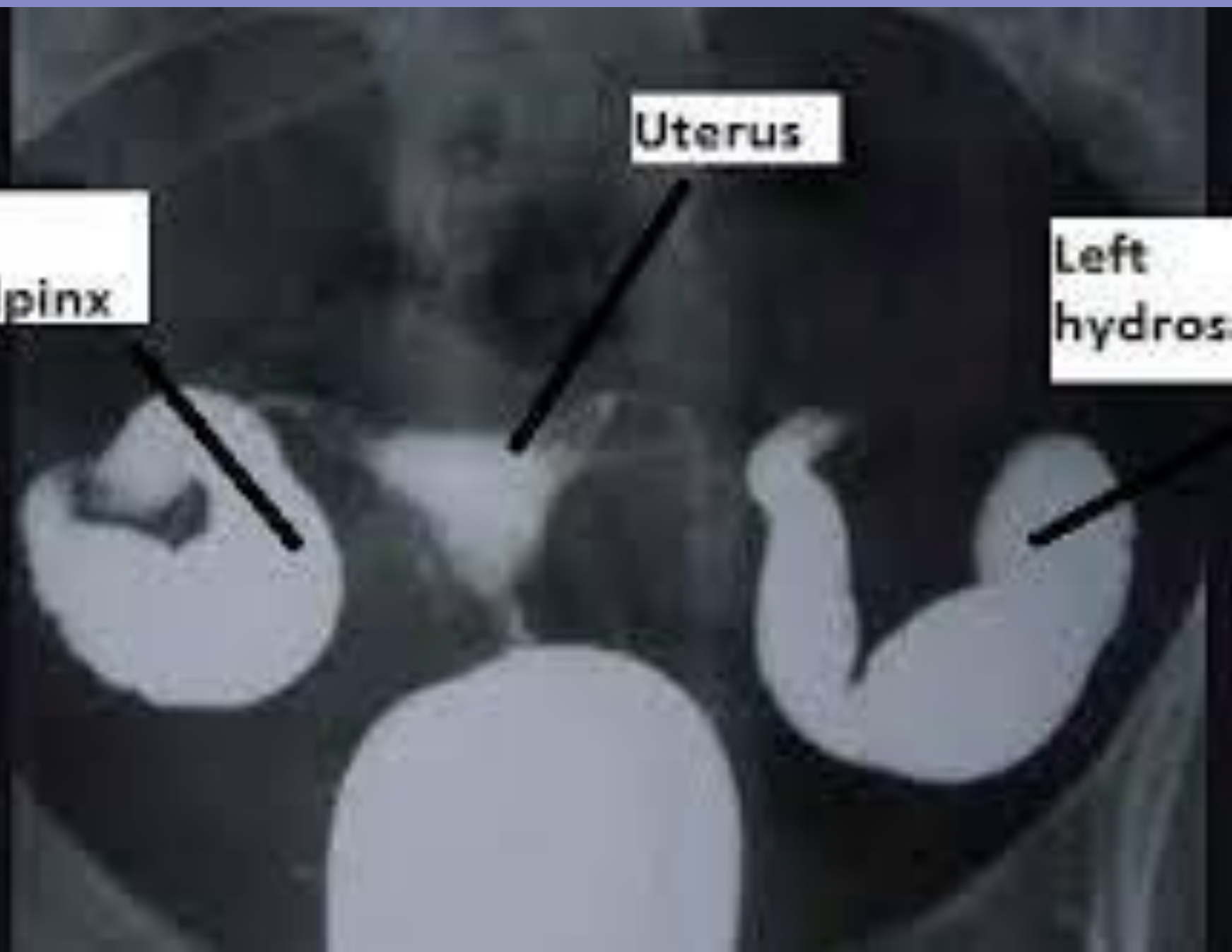
- Sonohysterosalpingiography using transvaginal ultrasound.
 - Diagnostic Laparoscopy
 - CT scan



Right
hydrosalpinx

Uterus

Left
hydrosalpinx



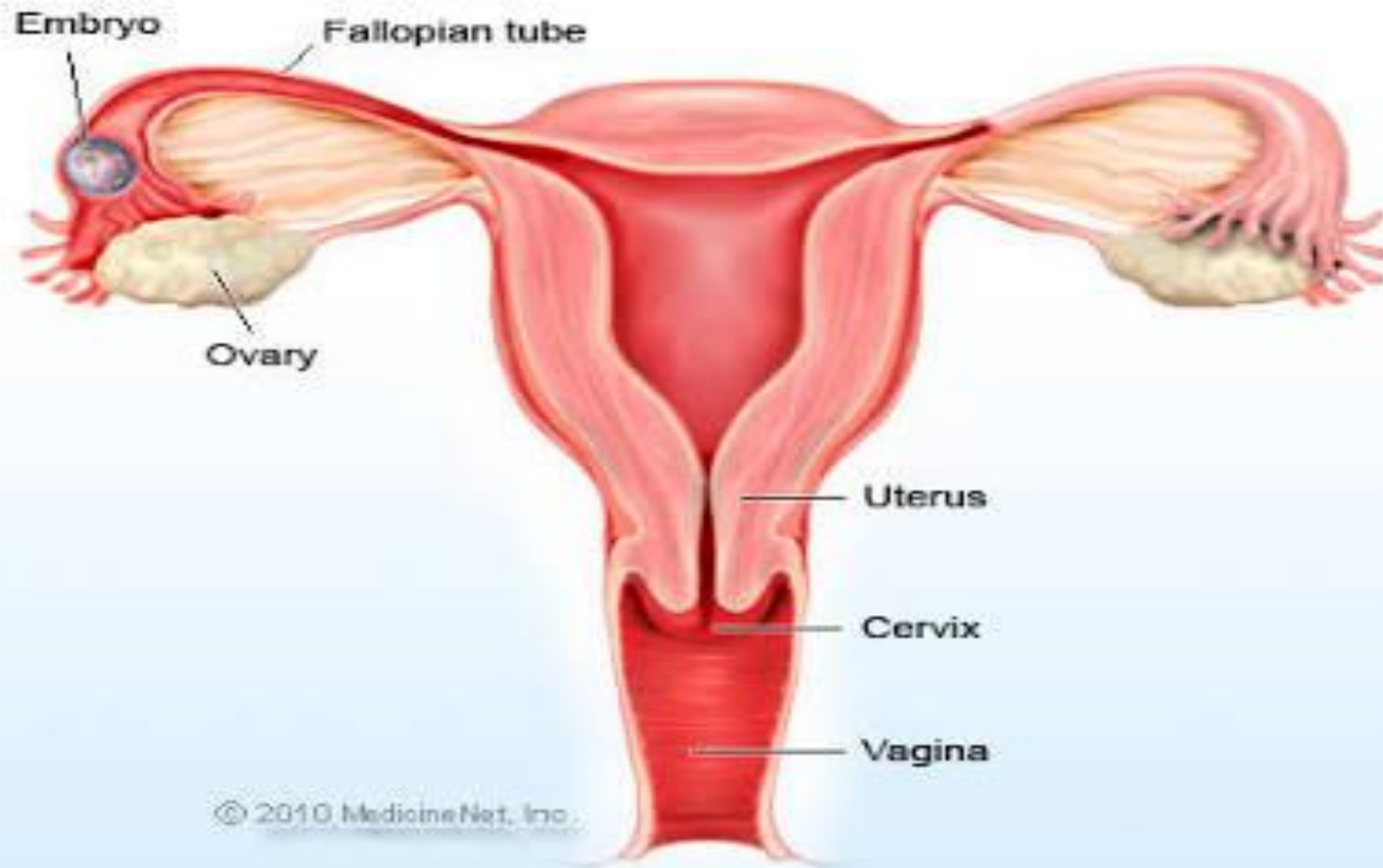
Tubal (ectopic) pregnancy:

- Symptoms:
 - Light vaginal bleeding
 - Pelvic pain
- Nausea and vomiting with pain
 - Sharp abdominal cramps
- Pain on one side of the body
 - Dizziness
 - Weakness
- Pain in shoulder, neck or rectum.

Diagnosis:

- Pelvic examination
 - Pregnancy test
- Ultrasonography

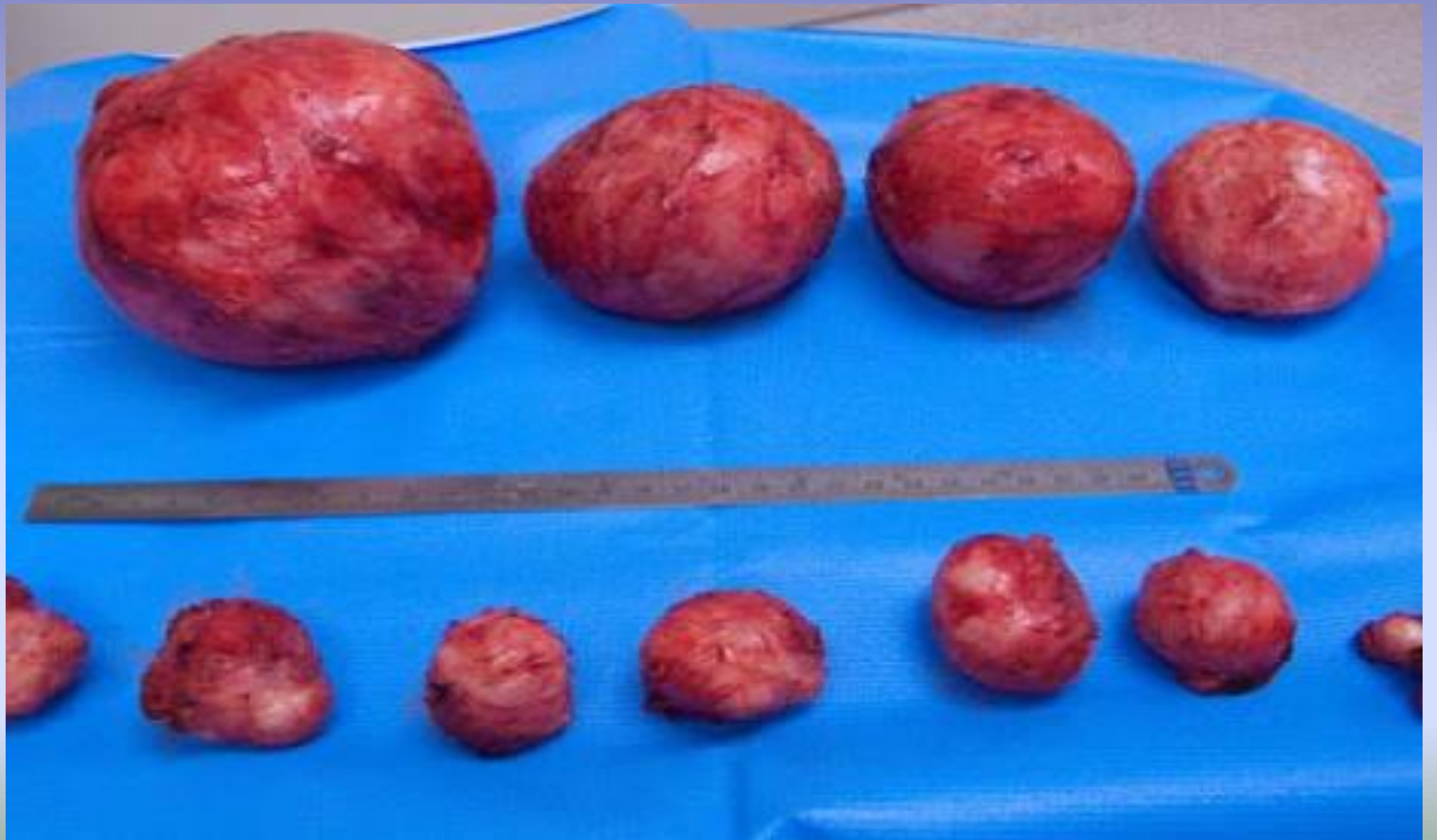Tubal Ectopic Pregnancy



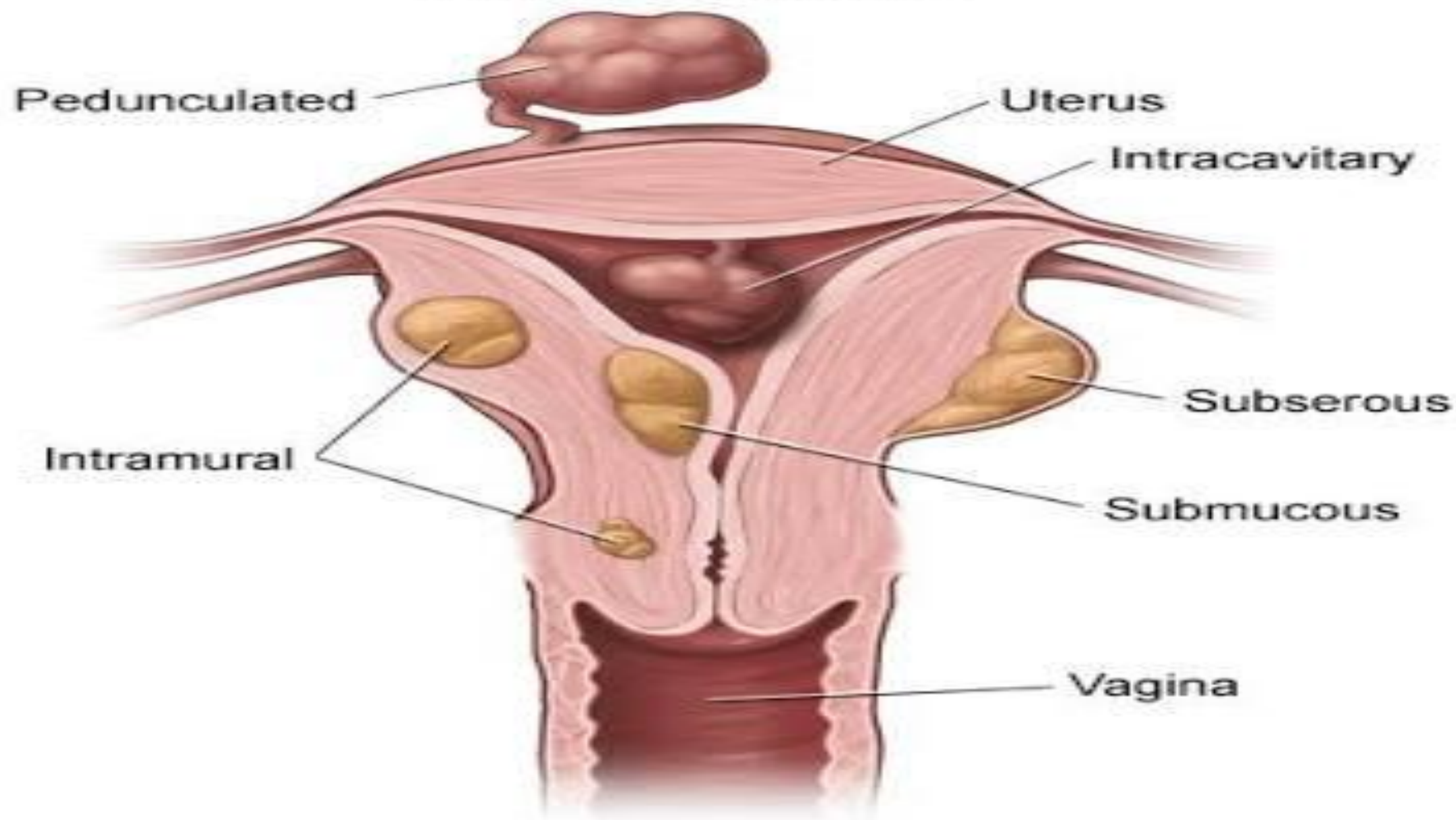
Fibroids:

Symptoms:

- Heavy bleeding between or during periods that includes blood clots
 - Pain in the pelvis and lower back
 - Increased menstrual cramping
 - Increased urination
 - Pain during intercourse
- Pressure or fullness in lower abdomen



Uterine Fibroids



Diagnosis:

- Ultrasonography
 - Pelvic MRI

Conclusion:

Different causes of mass in left iliac fossa in ladies only are Tubo-ovarian causes:

- Ovarian cyst or tumour
 - Hydrosalpnix
 - Pyosalpnix
- Tubal pregnancy
 - Fibroid

Resources:

www.webmd.com

www.mayoclinic.org

www.uptodate.com

Kasr-Eleiny book of General surgery

Thank

You